Bulletin No. 13 of the Department of Surgery
University of Lund, 221 85 LUND
1977

PANCREATIC AND INTESTINAL VEIN CATHETERIZATION WITH HORMONE ASSAY

A localization procedure for gastrointestinal endocrine tumours

STIG G INGEMANSSON

PANCREATIC AND INTESTINAL VEIN

CATHETERIZATION

WITH HORMONE ASSAY

A localization procedure for gastrointestinal endocrine tumors

Stig G Ingemansson
med. lic. Bl.

Akademisk avhandling
som för avläggande av medicine doktorsexamen
vid medicinska fakulteten vid Universitetet i Lund
kommer att offentligen försvaras å Föreläsningssal 3
Centralblocket, Lasarettet i Lund tisdagen den 31 maj
1977 kl. 09.15

From the Department of Surgery (Head: Prof. S. Bengmark), and Diagnostic Radiology (Head: Prof. O. Olsson), University Hospital, S-221 85 Lund, Sweden.

PANCREATIC AND INTESTINAL VEIN CATHETERIZATION WITH HORMONE ASSAY

A localization procedure for gastrointestinal endocrine tumors.

Stig G. Ingemansson

Lund 1977

All investigations were supported by grants from the Swedish Cancer Society (Proj. No. 76115), Fonden for Kraeftens Bekaempelse, and Mrs. M. Stephens Foundation.

Printed by

Illustration Department
Institute of Anatomy and Histology
University of Lund
Lund, Sweden

All investigations were supported by grants from the Swedish Cancer Society (Proj. No. 75115), Fonden for Kreftens Bekæmpelse, and Mrs. H. Stephens Foundation.

Printed by

Illustration Department
Institute of Anatomy and Histology
University of Lund
Lund, Sweden

The present thesis is based on the following papers:

I. Ingemansson, S., Lunderquist, A., Lundquist, I., Lövdahl, R. and Tibblin, S.: Portal and pancreatic vein catheterization with radioimmunologic determination of insulin.
Surg. Gynecol. Obstet. 141: 705-711, 1975.

II. Ingemansson, S., Holst, J., Larsson, L.-I. and Lunderquist, A.: Localization of glucagonomas by pancreatic vein catheterization and glucagon-assay.
Surg. Gynecol. Obstet. In press, 1977.

III. Ingemansson, S., Larsson, L.-I., Lunderquist, A. and Stadil, F.: Pancreatic vein catheterization with gastrin-assay in normal patients and in patients with the Zollinger-Ellison syndrome.
Submitted to Am. J. Surg.

IV. Ingemansson, S., Kühl, C., Larsson, L.-I., Lunderquist, A. and Lundquist, I.: Localization of insulinomas and islet cell hyperplasias by pancreatic vein catheterization and insulin assay.
Submitted to Surg. Gynecol. Obstet.

V. Ingemansson, S., Bengmark, S., Larsson, L.-I., Lunderquist, A. and Nilsson, G.: Aortal, caval and intestinal vein catheterization with substance-P-determination in patients with carcinoid tumors.
Submitted to Ann. Surg.

In the text the papers will be referred to by their Roman numerals.

The present thesis is based on the following papers:

I. Ingemansson, S., Lundgren, A., Lundqvist, I., Löwdahl, R. and Tibblin, S.: Portal and pancreatic vein catheterization with radioimmunologic determination of insulin.
Surg. Gynecol. Obstet. 141: 705-711, 1975.

II. Ingemansson, S., Melat, J., Larsson, L.-I. and Lundgren, A.: Localization of glucagonomas by pancreatic vein catheterization and glucagon-assay.
Surg. Gynecol. Obstet. In press, 1977.

III. Ingemansson, S., Larsson, L.-I., Lundgren, A. and Stadil, F.: Pancreatic vein catheterization with gastrin-assay in normal patients and in patients with the Zollinger-Ellison syndrome.
Submitted to Am. J. Surg.

IV. Ingemansson, S., Kühl, C., Larsson, L.-I., Lundgren, A. and Lundqvist, I.: Localization of insulinomas and islet cell hyperplasias by pancreatic vein catheterization and insulin assay.
Submitted to Surg. Gynecol. Obstet.

V. Ingemansson, S., Bengmark, S., Larsson, L.-I., Lundgren, A. and Nilsson, G.: Aortal, caval and intestinal vein catheterization with substance-P-determination in patients with carcinoid tumors.
Submitted to Ann. Surg.

In the text the papers will be referred to by their Roman numerals.

C O N T E N T S

Abbreviations

AIPD	=	anterior inferior pancreaticoduodenal vein
ASPD	=	anterior superior pancreaticoduodenal vein
CV	=	coronary vein
DP	=	dorsal pancreatic vein
GCT	=	gastrocolic trunk
GEV	=	gastroepiploic vein
HV	=	hemorrhoidal vein
ICV	=	ileocolic vein
IMV	=	inferior mesenteric vein
JIV	=	jejunal and ileal veins
LCV	=	left colic vein
MCV	=	middle colic vein
PIPD	=	posterior inferior pancreaticoduodenal vein
PSPD	=	posterior superior pancreaticoduodenal vein
PV	=	portal vein
RCV	=	right colic vein
RSV	=	rectosigmoid vein
SMV	=	superior mesenteric vein
SPL	=	splenic vein
SV	=	sigmoid vein
TP	=	transverse pancreatic vein
EC-cells	=	enterochromaffin cells
5-HT	=	5-hydroxytryptamin
HPP=PP	=	human pancreatic polypeptide
IRI	=	insulin-like immunoreactivity
SP	=	substance P
SPLI	=	substance P-like immunoreactivity

INTRODUCTION

A. Peptide hormone-producing cells. Cells with the capacity to produce peptide hormones are found throughout the body. Due to certain cytochemical, ultrastructural and tinctorial properties these cells are frequently grouped together and have been postulated to share a common embryological origin (Feyrter 1954, Pearse 1974, Fujita 1976).

Although the pancreatic islets were discovered already in 1868 (Langerhans 1868) new islet cell types are still discovered. Today the pancreatic islets have been shown to contain at least six distinct cell types: insulin-producing B-cells, glucagon-producing A-cells, pancreatic polypeptide-producing PP-cells, D-cells producing a somatostatin like peptide and two cell populations with as yet undiscovered peptide products; the EC and D_1 cells (Fig. 1).

The gastrointestinal tract is considered to contain two main groups of endocrine cells; enterochromaffin and non-enterochromaffin endocrine cells, differing with respect to their content of biogenic monoamines (usually 5-hydroxytryptamine). Both cell-systems are now known to be heterogeneous with respect to peptide production. The system of non-enterochromaffin cells comprise e.g. gastrin-, cholecystokinin- and secretin-producing cells whereas the 5-HT-containing enterochromaffin cells comprise at least three distinct types producing substance P, motilin or as yet undiscovered peptides (Pearse 1974, Polak 1974, Heitz 1976). In all probability the above mentioned pancreatic EC-cells are similar to the gastrointestinal EC-cells. Their peptide product has yet to be discovered. It should be noted that of the peptides mentioned, only insulin, glucagon, gastrin, cholecystokinin and secretin have acquired full status as hormones whereas the other peptides are considered as candidate hormones (Grossman 1975).

During recent years recognition of the multiplicity of functions of

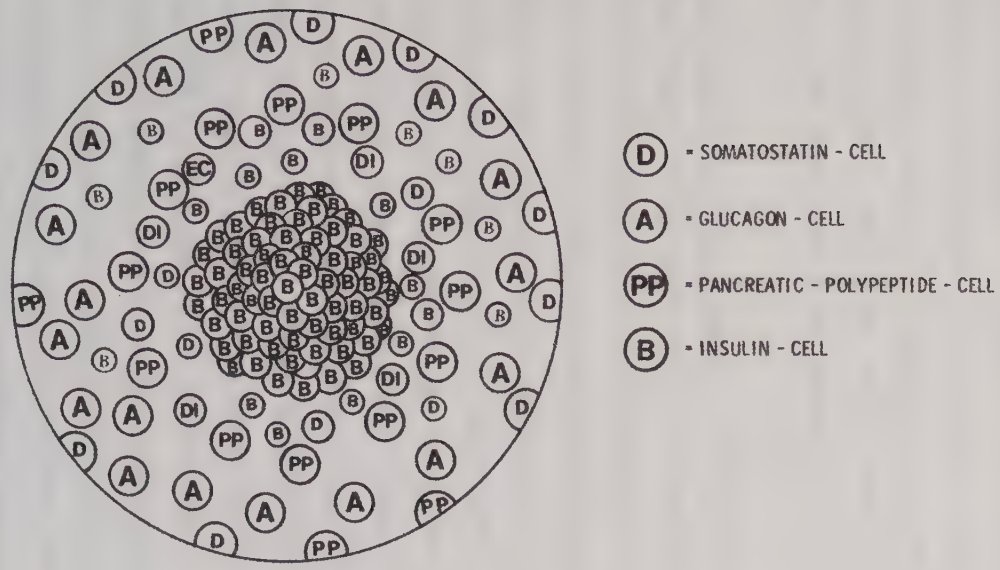

Cell type	Hormone	% of total islet-cell amount
B	Insulin	60 - 80 %
$A = A_2$	Glucagon	15 %
$D = A_1$	Somatostatin	5 - 10 %
PP	HPP	Less than 10% (age variation)
D_1	?	1 - 2 %

Fig. 1 Different endocrine cell types in a human pancreatic islet. (A few EC-cells may be seen.)

peptide hormones has begun to evolve. However, much information concerning these chemical messengers are still lacking. This gap in knowledge is evident in both the physiological, morphological and pathological field.

B. Endocrine tumors. All types of gastrointestinal and pancreatic peptides may be produced by endocrine tumors. Raised blood concentrations of one or more of these peptides are measurable with radioimmunoanalytical techniques, which are of major importance for diagnosis and monitoring of therapy.

a/ Pancreatic endocrine tumors. Insulin-producing pancreatic tumors were the first to be detected (Harrison et al 1924) and constitute still the most frequent type of endocrine pancreatic tumors. With the introduction of radioimmunoassays more insulinomas were detected and today their incidence is estimated to be one per million inhabitants per year. Other types of pancreatic endocrine tumors produce excessive amounts of gastrin and causes a syndrome of peptic ulceration and gastric hyperacidity (Zollinger & Ellison 1952). The secretory product(s) of endocrine tumors causing the watery diarrhoea syndrome (WDHA) (Werner & Morrison 1958) are proposed to be vasoactive intestinal polypeptide (VIP) (Bloom 1975) and human pancreatic polypeptide (HPP) (Larsson 1976). Also tumors producing excessive amounts of glucagon (Mallinson 1974) or somatostatin (Larsson 1977) have been noted to be associated with characteristic clinical abnormalities. A sixth group of pancreatic endocrine tumors seem not to produce characteristic clinically apparent symptoms. The diagnosis of this type of tumor will have to await the characterization of its secretory product(s).

b/ Carcinoid tumors. The term carcinoid was coined in 1907 (Oberndorfer 1907) to describe a type of intestinal tumor displaying

both malignant and benignant features. Since then the malignant potential of this type of tumor has been more readily appreciated and a characteristic syndrome due to secretory products from carcinoid tumors has been described (Thorson 1954, Hajdu 1974). A large number of agents have been proposed to cause this syndrome. Such candidates include kinins, 5-hydroxytryptamine, prostaglandins and substance P (sf Lancet editorial, 1964). Carcinoids contain cells morphologically identical with those of the enterochromaffin cell system and may be found in the gastrointestinal tract, pancreas, biliary tract, ovaries and bronchial tree.

C. Methods for the localization of endocrine tumors. A preoperative localization procedure is of outmost importance for a curative treatment of abdominal endocrine tumors - radical surgical extirpation. The vast number of available techniques serve to indicate the difficulties inherent in this task. Thus, abdominal palpation, gastrointestinal tract x-rays, ultrasound, scintiscan and arteriography are currently employed today. The best method available-arteriography - has an estimated accuracy of 40-60 per cent, and a false positive rate of 5 per cent in patients with insulinomas. Small tumors and islet hyperplasias cannot be detected with any of the conventional pre- or peroperative localization procedures. With gastrinomas these localization techniques show an estimated accuracy even lower than that for insulinomas. Glucagonomas, somatostatinomas and WDHA causing tumors are as yet rarely diagnosed tumors. Conclusions concerning the values of various localization procedures with these types of tumors can therefore not be made. Conceivably the accuracy would be in the same range as that for insulinomas and gastrinomas. Pancreatic endocrine tumors without known syndromes and peptide products are angiographically indistinguishable from the group of tumors with recognized syndromes and peptide products (Boijsen 1975). Carcinoids present a

troublesome group of tumors that usually are detected only when they have metastasized or grown to a large size (Boijsen 1974, Strasberg 1975). Hence, universably applicable localization procedures do not exist for these tumors.

D. Aims of the present work. No reliable and universally applicable technique for the preoperative localization of abdominal endocrine tumors is thus available. When the tumors or areas containing hyperplastic endocrine cells cannot be localized pre- or peroperatively the surgeon has to perform blind resections which may or may not remove the entire affected tissue (McCaughan 1935, Stefanini 1974, Fulton 1975). More accurate localization procedures have to be found and tested. An attractive way of localizing such tumors would be to demonstrate a pathologically raised arteriovenous hormone difference over the site of the tumor. Therefore simultaneous catheterizations of the aorta and the caval, portal, intestinal and pancreatic veins with phlebographies establishing the venous anatomy were carried out. Blood samples, taken from the various vascular areas, were assayed radioimmunochemically for a variety of peptide hormones. With that localization procedure tumors and endocrine cell hyperplasias producing excessive amounts of insulin, glucagon, gastrin, and substance P were investigated preoperatively. Further the catheterization technique was employed postoperatively to confirm surgical radicality, exclude the presence of metastasis and localize recurrences.

MATERIAL

A total of 31 patients, 14 females and 17 males, age range 27-73 years, $\bar{m}$ = 48, median = 43) were investigated. Sixteen of the patients, eight females and eight males, were investigated in order to localize gastrointestinal endocrine tumors (3 insulinomas, 2 islet hyperplasias causing hypoglycemia, 3 gastrinomas, 2 glucagonomas and 6 carcinoid

umors). In all, 27 investigations were performed in this group. ifteen of the patients were investigated with portal, pancreatic nd intestinal vein phlebography in order to exclude abdominal alignancy. In none of them was malignancy found. These patients ere used as the reference group.

ETHODS

A. Preoperative diagnosis. The preoperative diagnosis was established r suspected (patients nos. III and IV in paper IV) by means of case istories and laboratory tests. Ultrasound, scintiscan and arterio-raphy were used for conventional preoperative localization.

B. Catheterization procedures. The patients were examined after 8 hours of fasting. Patients nos. III and IV (paper IV) were investi-ated under general anaesthesia because of anxiety. The rest of the atients were investigated under local anaesthesia. Percutaneous ranshepatic portal vein catheterization was performed and subsequently ortography was carried out in order to establish the portal anatomy (Göthlin 1974, Hoevels 1977). Transfemoral caval and aortal catheters ere introduced and the aortal catheter was placed in the coeliac rtery. Blood samples were withdrawn from different caval and hepatic ranches and then the caval catheter was placed in the hepatic vein. he portal vein catheter was used for blood sampling from the portal ein stem, portal vein branches, pancreatic veins and intestinal veins. o exactly localize the tip of the catheter through which the blood amples were withdrawn, a series of films were taken, usually following anual injection of contrast medium. In the different schablons (Fig. 2 a, b; paper I Fig. 1) sampling localizations were plotted.

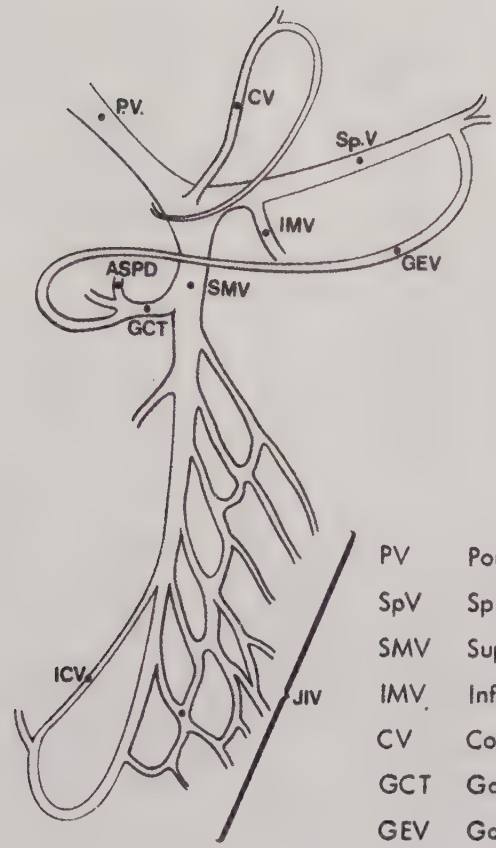

PV	Portal vein
SpV	Splenic vein
SMV	Superior mesenteric vein
IMV	Inferior mesenteric vein
CV	Coronary vein
GCT	Gastro colic trunc
GEV	Gastroepiploic vein
JIV	Jejunal and ileal veins
ICV	Ileocolic vein
ASPD	Anterior superior pancreatic-duodenal vein

Fig. 2 a. The superior mesenteric vein (SMV) and its tributaries.

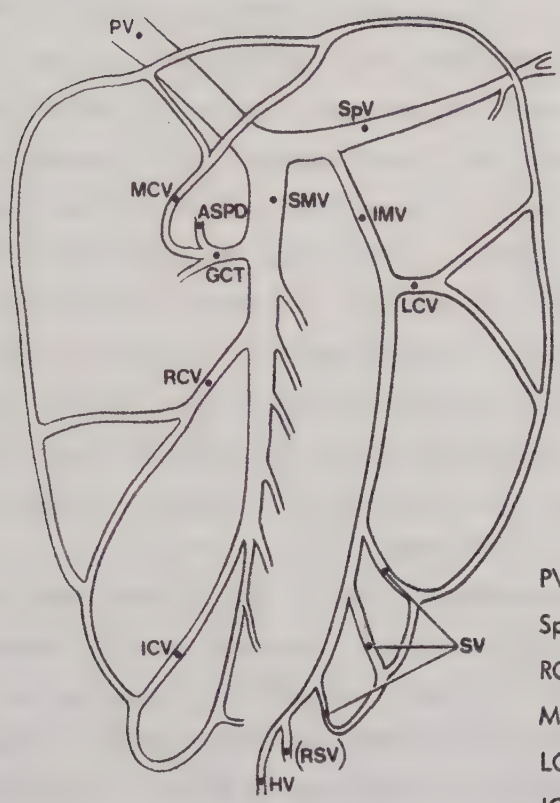

PV	Portal vein
SpV	Splenic vein
RCV	Right colic vein
MCV	Middle colic vein
LCV	Left colic vein
ICV	Ileocolic vein
SV	Sigmoid veins
RCV	Rectosigmoid vein
HV	Hemorrhoidal vein
SMV	Superior mesenteric vein
IMV	Inferior mesenteric vein
ASPD	Anterior superior pancreatico-duodenal vein

Fig. 2 b. The inferior mesenteric vein (IMV) and its tributaries.

C. Radioimmunological techniques. All blood samples were collected in ice-chilled tubes, centrifuged at 4° C and stored at -20° C until assayed. Samples for glucagon or substance P assay were collected in tubes containing Trasylol[R] and heparin. Serum concentrations of gastrin were determined by radioimmunoassay (antiserum No. 2604) as previously described (Rehfeld 1973, Stadil 1972). With the technique employed the four main components of circulating gastrin are measured with almost equimolar potency. Serum was assayed for insulin by a sensitive radioimmunoassay utilizing Wick separation technique (Örskov 1967). The antiserum used in this assay was produced by immunization of guinea-pigs with monocomponent porcine insulin (Novo Research Laboratories, Copenhagen, Denmark) and binds proinsulin and insulin with almost equimolar potency (Kühl 1975, Kühl 1976). Precision, accuracy and specificity of the assay have been given in detail elsewhere (Kühl 1975). Insulin was also assayed with an alcohol precipitation technique (Heding 1966). The antiserum used (M 29) was produced by immunization of guinea-pigs with porcine zink-protamine insulin emulsified in Freund's adjuvant. Chromatography of sera from samples containing high insulin immunoreactivity (paper no. IV, patient no. II) was performed on G-50 superfine Sephadex columns (1.6 x 100 cm). The eluates were assayed with both antisera. The contribution of proinsulin-like components to the total insulin immunoreactivity was determined with the Wick separation technique after gel chromatography on a Sephadex G-50 superfine column (1.6 x 100 cm) as described elsewhere (Kühl 1976). Glucagon was assayed with the technique described by Holst (Holst 1974). The substance P assay technique used has been described by Nilsson et al (Nilsson 1976). Blood glucose was determined by the oxidase method.

D. Immunocytochemical techniques. Tissue specimens obtained at surgery were frozen to the temperature of liquid nitrogen in a propane-propylene mixture, freeze-dried, vapor-fixed with formaldehyde (Björklund et al 1972) or diethylpyrocarbonate (DEPC) (Pearse 1975) and embedded in

paraffin in vacuo. Sections cut at 3 μ were deparaffinized and allowed to react with antisera against different polypeptides (cf I-V) (Larsson 1975). The site of antigen antibody reaction was revealed either by the PAP method of Sternberger or with fluorescinisothiocyanate (FITC)-labelled sheep anti-guinea-pig IgI or FITC-labelled sheep anti-rabbit IgG (SBL, Stockholm, Sweden). Specificity controls were those recommended by Sternberger (Sternberger 1974) and included the application of antigen-inactivated antisera.

E. Surgical techniques. At the explorative laparotomies a careful abdominal palpation and inspection was performed. The pancreas was approached through the gastrocolic omentum, the stomach being retracted upward and the transverse colon downwards. The Kocher-maneouver was fulfilled. Manuel palpation and inspection of the pancreas, duodenal loop, retroperitoneal space and splenic hilus was performed. Suspected pancreatic areas were further examined by fine needle aspiration biopsies. The pancreatic veins were visualized and pancreatic resections performed according to the venous anatomy and preoperative findings of arterio-venous hormone differences. The patients with carcinoid tumors were operated upon through right-sided transrectal incision. Tumor spread was assessed by palpation, inspection and biopsies, whereafter curative or palliative tumor extirpation was performed. During operation tissue specimens were collected for immunochemistry and immunocytochemistry.

F. Statistical methods. Plasma and sera concentrations of hormones in the reference groups are expressed as range, mean and median. Student´s t-test for paired data was used when comparing pre- versus postoperative hormone concentrations in the same vascular area. Analysis of variance was performed when calculating differences between hormone concentrations due to sampling times. For judging a possible decrease or increase of hormone concentration during the investigations analysis of regression was performed.

RESULTS AND DISCUSSION

A. Preoperative diagnosis. Preoperative diagnoses were established in all patients (except patients nos. III and IV in paper IV) by means of case histories and laboratory tests. Although hypoglycemia was evident in patients nos. III and IV (paper IV) no clear-cut indications for insulin-secreting tumors were obtained since upon fasting, blood glucose: insulin ratios were on most occasions normal. The catheterizations performed in these patients, however, indicated a pancreatic source of abnormally high insulin secretion.

B. Catheterization technique. Three routes can be used for gaining access to the portal vein system and its tributaries. Transumbilical portography (TUP) demands a surgical procedure and implies increased radiation of the hands of the examiner. Further the bend at the junction of the umbilical vein and the left main portal branch makes selective catheterization of portal vein branches difficult.

Transjugular transhepatic portography (TTP) demands a long catheter which makes the selective vein catheterization difficult.

Percutaneous transhepatic portography (PTP) performed with the technique described by Wiechel (1971) has been used in these studies. The technique allows easy access to the portal venous system and its tributaries (pancreatic veins, splanchnic veins). The method implies certain risks such as bleeding and bile leakage into the abdominal cavity. The technique, indications, contraindications and complications of percutaneous transhepatic portography and selective catheterization of the major and minor veins draining the splanchnic organs has recently been reported (Hoevels 1977). Serious complications such as bleeding into the abdominal cavity were seen in 4 out of 200 patients and bile leakage in only 2 cases. The mortality rate was nil. The advantage of the PTP method was obvious and it has therefore been used in this investigation. Due to

anxiety two patients had to be examined under general anaesthesia. In all other cases local anaesthesia was employed. The portal vein puncture was successfully performed at the first attempt in most of the patients. In all the patients a right portal vein branch was punctured and thereby successful catheterization of pancreatic and intestinal veins was easily done (Hoevels 1977). Phlebography of the portal vein and its tributaries failed to provide information concerning the tumor localization in addition to that obtained with arteriography. It was, however, useful for establishing the venous anatomy and the positions of the catheter during the sampling maneouvers (paper I, Fig. 11; paper II, Fig. 1 a, b, c; paper IV, Fig. 6 a,b; and paper V, Fig. 6 a, b, c; Ingemansson 1977).

As many portal vein branches, intestinal and pancreatic veins as possible were then catheterized. Blood samples could be withdrawn even from very small veins. Occasionally short lasting contractions of minute veins around the catheter tip occurred; blood sampling was always performed after the spasm was released. Changed blood flow as caused by the catheter maneouvers was not evaluated in every case. Drip counting during 3-5 minutes was sometimes performed and indicated a rather constant rate of blood flow. Occasionally blood sampling was impossible from catheterized veins. The tip of the catheter was found directed against the wall of the vein. Therefore a side hole one millimeter proximal to the tip of the catheter was used. During fluoroscopy contrast medium was injected in order to assess or exclude the possibility of entrance of blood (through the side holes) from other veins than that catheterized. If such "stealing" was suspected or proven notes were made on the samples. Samples withdrawn close to the orifice of the veins contained lower concentrations of hormone compared to samples withdrawn from a distal position in the vein (paper IV, Fig. 1 c,samples nos. 11-15; Fig. 3 a, samples nos. 7, 8, 9 and 12, 13). This phenomenon could be an effect of stealing of blood from the splenic vein. At some occasions the tip of the catheter slipped away from the vein during the sampling maneouver. This prompted us to check the position of the catheter tip

after each sampling.
Hormone concentrations showed significant differences between sampling times during some of the investigations (paper I-V; Appendices 1-4). These fluctuations did not disturb the final conclusions concerning the localization of gastrin-, insulin- or glucagon-secreting tumors.

In all the patients the highest hormone concentrations were found in samples withdrawn from the portal vein system (I-V) thereby extra-portal tumors were excluded. Pathologically high hormone concentrations were found in veins draining pancreatic tumors or hyperplastic areas. Extrapancreatic tumors could thus be excluded (Marks 1971, Smith 1975, Zollinger 1975).

In patient no. I (paper IV) we failed to withdraw blood samples preoperatively from the tumor draining vein or veins. Sample no. 3 (paper IV, Fig. 1 a) was taken from the splenic vein, close to the orifice of the tumor-draining vein. As seen from paper IV, Fig. 2 a, samples nos. 2, 22, 24; and Fig. 5, samples nos. 13, 14, 16 and 17, the highest value is found in the tumor-draining veins. Other samples contain sufficient insulin for the localization of a tumor in the distal part of the pancreas (paper IV, Fig. 5, samples nos. 13, 14, 16 and 17). Besides in patients nos. III and V (paper IV) very low insulin concentrations were found in the veins draining tumor-free areas. The localization, and thereby confirmation of the diagnosis, is thus best performed when samples are withdrawn from several pancreatic veins including the tumor-draining veins.

Postoperative catheterization technique did not differ from the preoperative technique. Changes in venous anatomy was clearly indicated by phlebography. Selective pancreatic vein catheterization could successfully be performed (paper I-V).

No serious complications occurred in the patients. In patient no. II (paper IV) a small hepatic hematoma was noted after the preoperative catheterization.

C. Insulin-producing tumors and islet cell hyperplasias (insulinomas, paper I and IV). Preoperative conventional localization procedures were in agreement with the catheterization results and the preoperative findings in patients nos. I and II. During operation of patient no. II the tumor could not be seen or palpated. The vein known to contain high insulin concentrations was followed (paper IV, Fig. 2 a, samples nos. 22-24) and in the pancreatic parenchyma a small soft tumor was found. In patients nos. III and IV resection of the area drained by the veins containing high insulin levels was performed since no tumor could be localized at operation. Subsequent morphological studies revealed the presence of a localized islet cell hyperplasia in these two patients. In patient no. V the tumor could only be localized preoperatively with a catheterization technique. However, during operation a tumor was detected by palpation and inspection of the dorsal side of the pancreatic tail. The tumor was by fine needle aspiration biopsy found to be endocrine. The venous drainage of the tumor was in agreement with the phlebographic findings and the arteriovenous insulin differences. In patient no. III the preoperative catheterization was performed during glucose infusion (paper IV) and blood glucose values were above the normal range. This might have explained the high insulin concentration in the tail of the pancreas but since other pancreatic veins contained much lower insulin concentrations a pathological insulin source was suspected (paper IV, Fig. 3 a, samples nos. 7, 8, 9 and 14). Catheterization of the patient two months after operation revealed normal insulin concentrations in all veins with a possible exception for the vein draining the distal part of the pancreatic remnant (paper IV, Fig. 3 b). That vein was recatheterized 8 months later and found to contain pathological high insulin

concentrations, though very low blood glucose levels, indicating recurrence (paper IV, Fig. 3 c and 6 b, c).

D. Glucagon-producing tumors (glucagonomas, paper II). The tumors were preoperatively localized with both angiography and pancreatic vein catheterization and peroperatively with palpation and inspection. Clear-cut arteriovenous differences were detected with the catheterization technique. The recently described glucagonoma syndrome (Mallinson 1974) will no doubt provide means for early detection of patients with glucagon-producing tumors. Thus preoperative localization of small tumors will have to be accomplished. The data presented suggest the triple catheterization technique as a suitable procedure.

In patient no. I neither arteriovenous hormone difference (glucagon and insulin) nor palpation or inspection during operation could localize the liver metastases found at the portography. The portographic findings were suspected to be false positive. However, mixed endocrine pancreatic tumors as in this patient may cause deposit of only one of the endocrine cells (Larsson 1975). Therefore normal glucagon concentration across the liver could be present even with liver metastasis if due to insulin-secreting tumors.

E. Gastrin-producing tumors (gastrinomas, paper III). Tumors belonging to this group are frequently multiple and malignant (Stremple 1975, Zollinger 1976). No useful procedure for their preoperative localization exists. Even during operation it is difficult or impossible to evaluate whether single or multiple tumors are present. Therefore the treatment is often concerned with a target organ - the stomach (Wilson 1973, Stremple 1975, Creutzfeld 1975). The catheterizations performed indicated the presence of gastrin-producing tumors in the two patients studied preoperatively. In patient no. III radical tumor extirpation was obtained whereas in patients nos. I and II the presence of

metastasis precluded this. Due to the high malignancy rate of gastrin-producing tumors (Zollinger 1976) measures for early diagnosis and exact preoperative localization are needed. Besides the advent of histamin H_2-receptor antagonists which inhibit acid secretion (Stage 1976, Bonfils 1977), may prevent complications caused by hypersecretion. Combined with a preoperative, accurate localization procedure, extirpation of tumors may be attempted and if successfully will be the therapy of choice also in patients with gastrinomas.

F. Carcinoid tumors (paper V). Based on the initial observation of high levels of substance P-like immunoreactivity (SPLI) (Håkansson 1977) in carcinoid tumors preoperative catheterizations were performed in carcinoid patients. Pathologically raised arteriovenous SPLI-differences were detected over carcinoids that subsequently were shown to contain substance P. Not all carcinoids were found to contain SPLI whereas all contained 5-HT. On the basis of this and other findings (Pearse 1974, Pearse 1975, Heitz 1976) it is suggested that 5-HT storing carcinoids constitute a heterogeneous group of tumors with respect to peptide production. Since a significant proportion of carcinoids (four out of six in the present series) secrete and store substance P-like immunoreactivity, radioimmunoassays may be expected to aid in the early recognition and localization of many of these tumors (Skrabanek 1977). Interestingly, during the investigations two of our carcinoid patients had flushing episodes. Starting simultaneously with the flushes the tumoral secretion of SPLI increased (paper V, Fig. 1, 3). On purely theoretical grounds a substance P-like substance has previously been suggested to contribute to the manifestations of the carcinoid syndrome (editorial, Lancet 1964). The present data indicate that this suggestion may well be true although a larger material will have to be studied before any firm conclusions can be reached. Whether the substance P-like immunoreactivity observed reflects tumoral production of the peptide described by von Euler and

Gaddum (von Euler 1931) remains to be elucidated. Our data emphasizes the usefulness of substance P determination for diagnosis of carcinoids (paper V, patient no. VI). Our data also emphasizes the usefulness of substance P determinations in combination with the catheterization technique for localizing these tumors.

CONCLUSIONS

1. Simultaneous aortal, caval and portal vein catheterization combined with selective pancreatic and intestinal vein catheterization and blood sampling for hormone assay is possible to perform in patients with gastrointestinal endocrine tumors before and after operation.

2. Localized, high, arteriovenous hormone differences are found in patients with gastrointestinal endocrine tumors and hyperplasias.

3. Thus obtained arteriovenous hormone differences are of great importance for obtaining radical extirpation of the tumors.

4. The catheterization procedure was able to localize tumors and hyperplasias even when other localization procedures failed.

5. In four out of six patients with carcinoid tumors substantial amounts of substance P was found in both primary tumors and metastasis.

6. The catheterizations indicated that some carcinoids actively secrete substance P-like material detectable with a radioimmunoassay. The SPLI-secretion was intermittent but allowed ready recognition of pathological arteriovenous hormone differences. (Fig. 3)

SUMMARY

Simultaneous aortal, caval, and portal catheterization with selective pancreatic and intestinal vein catheterization for blood sampling and hormone assay has been performed in patients with gastrinomas, insulinomas, islet cell hyperplasias, glucagonomas and carcinoids. The arteriovenous hormone differences have proved to be valuable guides to radical resections of tumors as well as hyperplasias. The investigations were performed without serious complications. This functional approach to diagnosis as well as localizations seems to

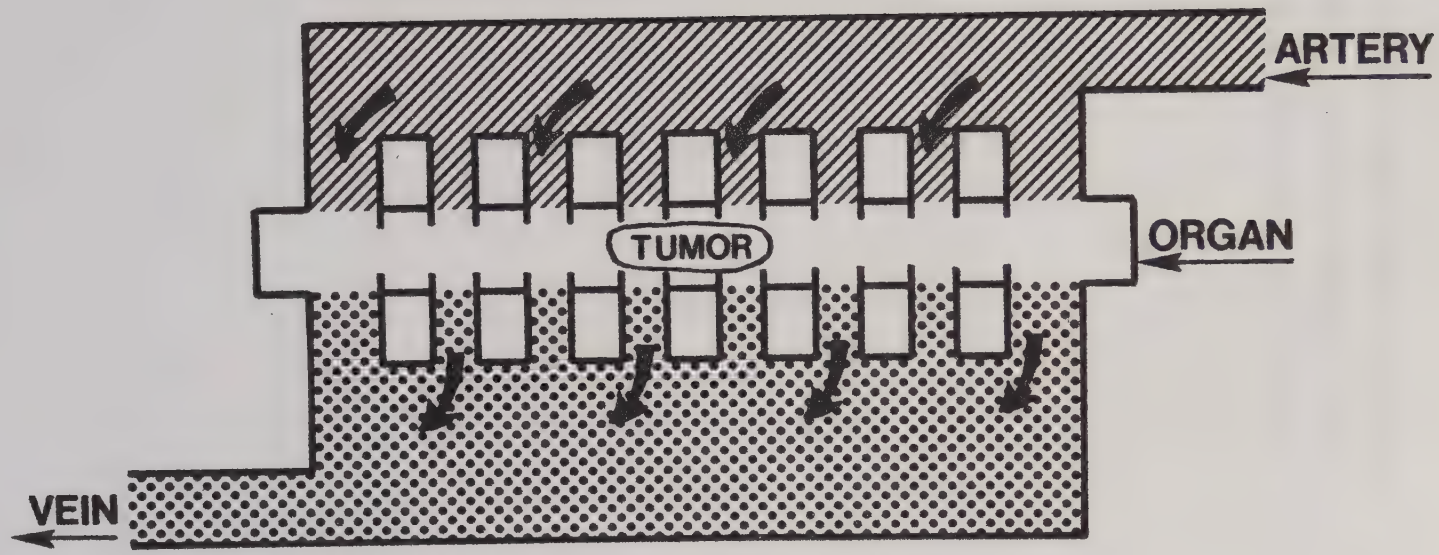

Fig. 3

Pathological high venous hormone concentrations have been used for localization of pheochromocytomas (von Euler 1957, Harrisson 1974) and parathyroid adenomas (Wells 1973).

In this study arteriovenous hormone differences have been used for localization of insulin-, glucagon-, gastrin- and SPLI-secreting tumors (I-V).

be superior to conventional morphological procedures like ultrasound, scintiscan, phlebography and arteriography. Hence, it is suggested for use in patients with established or suspected endocrine tumors.

REFERENCES

Björklund A., Falck B. and Owman Ch.: Fluorescence microscopic and microspectrofluorometric techniques for the cellular localization and characterization of biogenic mono-amines. IN: Berson SA, ed., Methods of investigative and diagnostic endocrinology, vol. 1, Rall JE, Kopin IJ, eds., The thyroid and biogenic amines, p. 318-368. Amsterdam: North-Hollande Publ Co 1972.

Bloom S.R., Polak J.M. and Pearse A.G.E.: Vasoactive intestinal peptide and watery diarrhea syndrome. Lancet, 2: 14, 1973.

Bonfils S., Bernier J.J., Mignon M., Lambert R., Bernades P., L'Hirondel C., Accary J.-P. and Kloeti G.: Metiamide treatment in five patients with Zollinger-Ellison syndrome. Digestion, 15: 43, 1977.

Boijsen E., Kaude J. and Tylén U.: Radiologic diagnosis of ileal carcinoid tumors. Acta Radiol. Diagn., 15: 65, 1974.

Boijsen E.: Inactive malignant endocrine tumors of the pancreas. Radiologe, 15: 177, 1975.

Creutzfeldt W., Arnold R., Creutzfeldt C. and Trach N.S.: Pathomorphological, biochemical and diagnostic aspects of gastrinomas (Zollinger-Ellison syndrome). Hum. Pathol., 6: 47, 1975.

Editorial: Lancet, i 539, 1964.

Euler v. U.S. and Gaddum J.H.: An unidentified depressor substance in certain tissue extracts. J. Physiol. (Lond.), 72: 74, 1931.

Euler v. U.S. and Ström G.: Present status of diagnosis and treatment of phaeochromocytomas. Circulation, 15: 5, 1957.

Feyrter F.: Über die peripheren endocrinen (Paracrinen) Drüsen des Menschen. Wilhelm-Maudrich, Wien-Düsseldorf, 1954.

Fujita T.: The gastro-enteric endocrine cell and its paraneuronic nature. IN: Chromaffin, Enterochromaffin and Related Cells. (Edit. by R.E. Coupland and T. Fujita, Elsevier Scientific Publ. Co. Amsterdam-Oxford-New York, pp. 191-208, 1976.

Fulton R.E., Sheedy P.F., McIlrath D.C. and Ferris D.O.: Preoperative angiographic localization of insulin-producing tumors of the pancreas. Radiology, 123: 367, 1975.

Grossman M.J.: Candidate hormones of the gut. Gastroenterology, 67: 730, 1974.

Göthlin J., Lunderquist A. and Tylén U.: Selective phlebography of the pancreas. Acta Radiol. Diagn., 15: 474, 1974.

Hajdu S.I., Winawer S.J. and Myers W.P.L.: Carcinoid tumors. Am. J. Clin. Pathol., 61: 1521, 1974.

Harris S.: Hyperinsulinism and dysinsulinism. J. Am. Med. Assoc.,83: 729, 1924.

Harrisson T.S. and Freier D.R.: Pitfalls in the technique and interpretation of regional venous sampling for localizing phaeochromocytoma. Surg. Clin. North Am., 54: 339, 1974.

Heding L.: A simplified insulin radioimmunoassay method. In: Donato L. et al (eds.): Labelled proteins in tracer studies, pp. 345-350. Brussels: Euratom, 1966.

Heitz Ph., Polak J.M., Timson C.M. and Pearse A.G.E.: Enterochromaffin cells as the endocrine source of gastrointestinal substance-P. Histochemistry, 49: 343, 1976.

Hoevels J., Lunderquist A. and Tylén U.: Percutaneous transhepatic portography. Acta Radiol. Diagn. In press. 1977.

Holst J. and Aasted B.: Production and evaluation of glucagon-antibodies for radioimmunoassay. Acta endocrinol., 77: 715, 1974.

Håkansson R., Bengmark S., Brodin E., Ingemansson S., Larsson L.-I., Nilsson G. and Sundler F.: Substance P-like immunoreactivity in intestinal carcinoid tumors. Nobel symp. on substance P. Stockholm 1976. To be published 1977.

Kühl C.: Glucose metabolism during and after pregnancy in normal and gestational diabetic women. Acta endocrinol., 79: 709, 1975.

Kühl C.: Serum proinsulin in normal and gestational diabetic pregnancy. Diabetologia, 12: 295, 1976.

Langerhans P.: Dissertation. Berlin: G. Lange, 1869.

Larsson L.-I., Grimelius L., Håkansson R., Rehfeld J.F., Stadil F., Holst J., Angervall L. and Sundler F.: Mixed endocrine pancreatic tumors producing several peptide hormones. Am. J. Pathol. 79: 271, 1975.

Larsson L.-I.: Human pancreatic polypeptide, vasoactive intestinal polypeptide, and watery diarrhea syndrome. Lancet II: 149, 1976.

Larsson L.-I., Hirsch M.A., Holst J.J., Ingemansson S.G., Kühl C., Lindkaer Jensen S., Lundquist G., Rehfeld J.F. and Schwartz T.W.: Pancreatic somatostatinoma, clinical features and physiological implications. Lancet, in press, 1977.

Mallinson C.N., Bloom S.R., Warin A.P., Salmon P.R. and Cox B.: A glucagonoma syndrome. Lancet II: 1, 1974.

McCaughan J.M.: Subtotal pancreatectomy for hyperinsulinism. Ann. Surg., 101: 1336, 1935.

Marks V.: Diagnosis of insulinoma. Gut, 12: 835, 1971.

Nilsson G., Pernow B., Fischer H.G. and Folkers K.: Presence of substance P-like immunoreactivity in plasma from man and dog. Acta Physiol. Scand, 94: 542, 1975.

Oberndorfer S.: Karzinoide Tumoren des Dünndarms. Frankfurt Z. Pathol., 1: 426, 1907.

Pearse A.G.E., Polak J.M., Bloom S.R., Adams C., Dryburgh J.R. and Brown J.C.: Enterochromaffin cells of the mamalian small intestine as the source of motilin. Virchows Archiv (Cell Pathol.), 16: 111, 1974.

Pearse A.G.E., and Polak J.M.: Endocrine tumors of neural crest origin: Neurolophomas, apudomas and the APUD-concept. Medical Biol., 52: 3, 1974.

Pearse A.G.E., Polak J.M., Adams C. and Kendall P.A.: Diethylpyrocarbonate, a vapour-phase fixative for immunofluorescence studies on polypeptide hormones. Histochem. J., 6: 347, 1974.

Pearse A.G.E. and Polak J.M.: Immunocytochemical localization of substance P in mammalian intestine. Histochemistry, 41: 373, 1975.

Rehfeld J.F., Stadil F. and Rubin B.: Production and evaluation of antibodies for the radioimmunoassay of gastrin. Scand J. Clin. Lab. Invest., 30: 221, 1972.

Skrabanek P., Cannon D., Kirrane J., Legge D. and Powell D.: Circulating immunoreactive substance P in man. Ir. J. Med.Sci. pp. 399, 1977.

Smith L.H.: Ectopic hormone production. Surg. Gynecol. Obstet., 141: 443, 1975.

Stadil F. and Rehfeld J.F.: Determination of gastrin in serum. Scand. J. Gastroenterol., 8: 101, 1973.

Stage J.G., Rune S.J., Stadil F. and Worning H.: Treatment of Zollinger-Ellison patients with Cimetidine[R]. Proceedings of second international symposium on histamin H_2-receptor antagonists. Excerpta Medica, Amsterdam, 306, 1976.

Stefanini P., Carboni M., Patrassi N. and Basoli A.: The surgical treatment of occult insulinomas: a review of the problem. Br. J. Surg., 61: 1, 1974.

Stefanini P., Carboni M., Patrassi N. and Basoli A.: The value of arteriography in the diagnosis and treatment of insulinomas. Am. J. Surg., 131: 354, 1976.

Sternberger L.A.: Immunocytochemistry. Englewood Cliffs N.J., Prentice-Hall Inc., 1974.

Strasberg Z., Hyland J., Salem S., Wilderspin K. and Tuttle R.J.: The role of angiography in the management of intestinal carcinoid. Angiology, 26: 573,1975.

Stremple J.F.: Gastrinomas (gastrin-producing tumors). Surg. Clin. North Am., 55: 303, 1975.

Thorson A., Biörck G., Björkman G. and Waldenström J.: Malignant carcinoid of the small intestine with metastases to the liver, valvular disease of the right side of the heart (pulmonary stenosis and tricuspid regurgitation without septal defects), peripheral vasomotor symptoms, bronchoconstriction, and an unusual type of cyanosis. A clinical and pathologic syndrome. Amer. Heart J., 47: 795, 1954.

Verner J.V. and Morrison A.B.: Islet cell tumor and a syndrome of refractory watery diarrhea and hypocalemia. Am. J.Med., 25: 374, 1958.

Wells S.A., Doppman J.L., Bilezikian J.P., Shinkin M.P., Powell D., Ketcham A.S. and Aurbach G.D.: Repeated neck exploration in primary hyperparathyreoidism: Localization of abnormal glands by selective thyroid arteriography, selective venous sampling and radioimmunoassay. Surgery, 74: 678, 1973.

Wiechel K.-L., Kulling K.G., Marions O., Erwald R. and Lindberg K.: Direkt portografi. Nord. Med., 86: 1255, 1971.

Wilson S.D.: Ulcerogenic tumors of the pancreas; the Zollinger-Ellison syndrome. In: The Pancreas. Ed. L.C. Carey: The C.V. Mosby Company, pp. 295, 1973.

Zollinger R.M. and Ellison E.H.: Primary peptic ulcerations of the jejunum associated with islet cell tumors of the pancreas. Ann. Surg., 142: 709, 1955.

Zollinger R.M.: Islet cell tumors and the alimentary tract. Am. J. Roentgenol., 126: 933, 1976.

Örskov H.: Wick-chromatography for the immunoassay of insulin. Scand. J. Clin. Lab. Invest., 20: 297, 1967.

Acknowledgements

I want to express my profound gratitude to Professor Stig Bengmark, my chief and one of my scientific teachers, for never failing encouragement and guidance.

Professor Olle Olsson and Professor Jens Rehfeld for placing laboratory facilities to our disposal.

My profound gratitude is conveyed to my friends and scientific teachers, Assistant Professor Anders Lunderquist and Assistant Professor Lars-Inge Larsson, who have guided, encouraged and advised me in all my works.

Miss Monica Lundin and Miss Karin Jönsson for skilful secretarial assistance.

Miss Kerstin Ahldin and Mrs. Britt Englesson for skilful technical assistance.

Mrs. Karin Nilsson for illustrations.

Mr. Ove Bengtsson and Mr. Sten Håkansson for performing the printings.

Mrs. Gillian Sjödahl, who revised the English text.

Assistant Professor Claus Rerup for statistical advice.

Appendix no. 1

Preoperatively

	a. coel.	v. hep.	v. p. centr.
a/ sample no 1	1200	1580	1640
sample no 2	1270	1440	1930
sample no 3	1460	1880	2150
sample no 4	1660	1900	2400

	S.S.	D.F.	M.S.	F.	P.
b/ sampling times	0.033851	3	0.011284	14.13**	<0.01
vascular areas	0.053254	2	0.026627	33.33**	<0.01
exp. error	0.003994	5	0.000799		

Table I. a/ Preoperative glucagon concentrations (pg/ml) in blood samples withdrawn simultaneously from the coeliac artery, main hepatic vein and main portal trunk in patient no. I. Sampling was repeated four times in the course of two hours.

b/ Analyses of variance (F-test) performed on log. glucagon concentrations in a.

Appendix no. 2

Postoperatively

	a. coel.	v. hep.	v. p. centr.
a/ sample no 1	42	76	104
sample no 2	74	96	103
sample no 3	80	136	160
sample no 4	74	120	156
sample no 5	74	130	174

	S.S.	D.F.	M.S.	F.	P.
b/ sampling times	0.125271	4	0.031318	12.59**	< 0.01
vascular areas	0.246345	2	0.123173	49.51***	< 0.001
exp.error	0.019853	8	0.002482		

Table II. a/ Postoperative glucagon concentrations (pg/ml) in blood samples withdrawn simultaneously from the coeliac artery, main hepatic vein and main portal trunk in patient no. I. Sampling was repeated five times in the course of two hours.

b/ Analyses of variance (F-test) performed on log. glucagon concentrations in a.

Appendix no. 3

Preoperatively

	a. coel.	v. hep.	v. p. centr.
a/ sample no 1	1100	2000	
sample no 2	1280	2100	
sample no 3	700	1400	
sample no 4	520	2000	1220
sample no 5	1080	1950	
sample no 6	1550	2180	
sample no 7	1050	1400	
sample no 8	1200	2200	
sample no 9	950	1200	
sample no 10	990	1500	1600, 1750, 1600

	S.S.	D.F.	M.S.	F.	P.
b/ sampling times	0.162269	9	0.018030	1.92	N.S.
vascular areas	0.296594	1	0.296594	31.60***	< 0.001
exp. error	0.084441	9	0.009382		

Table III. a/ Preoperative glucagon concentrations (pg/ml) in blood samples withdrawn simultaneously from the coeliac artery, main hepatic vein and main portal trunk in patient no. II. Sampling was repeated ten times in the course of two hours. At two hours three samples were withdrawn from the portal vein with ten seconds interval.

b/ Analyses of variance (F-test) performed on log. glucagon concentrations in a.

Postoperatively

	a. coel.	v. hep.	v. p. centr.
a/ sample no 1	missed	204	
sample no 2	170	270	450
sample no 3	120	140	
sample no 4	94	122	
sample no 5	100	142	
sample no 6	106	152	176, 200

	S.S.	D.F.	M.S.	F.	P.
b/ sampling times	0.108625	4	0.027156	21.36**	< 0.01
vascular areas	0.047599	1	0.047599	37.44**	< 0.01
exp. error	0.005084	4	0.001271		

Table IV. a/ Postoperative glucagon concentrations (pg/ml) in blood samples withdrawn simultaneously from the coeliac artery, main hepatic vein and main portal trunk in patient no. II. Sampling was repeated six times in the course of two hours. The two portal vein samples at sample time no. 6 were withdrawn with ten seconds interval.

b/ Analyses of variance (F-test) performed on log. glucagon concentrations in a.

	Pat. no. 1		Pat. no. 2	
	Preop.	Postop.	Preop.	Postop.
v. hep. dx (main stem)	1900 (2)	130 (2)	1500 (9)	150 (5)
v. hep. dx (lat. segm.)	2030 (2)	-	-	-
v. hep. sin. (main stem)	-	150 (6)	1900 (4)	-
v. hep. sin. (lat. segm.)	1850 (3)	206 (4)	-	-
v. hep. sin. (med. segm.)	1980 (2)	-	-	-

Table V. Glucagon concentrations (pg/ml) and within brackets, insulin concentrations (uU/ml) in different hepatic veins from patient no. I and no. II before and after operation.

AORTAL, CAVAL AND INTESTINAL VEIN CATHETERIZATION WITH SUBSTANCE-P DETERMINATION IN PATIENTS WITH CARCINOID TUMORS.

Stig Ingemansson[1], M.D., Stig Bengmark[1], Prof., Lars-Inge Larsson[2], M.D.
Anders Lunderquist[3], M.D. and Göran Nilsson[4], M.D.

Departments of Surgery[1], Diagnostic Radiology[3], University of Lund, S-221 85 Lund, Institute of Pharmacology[4], KS, Stockholm, Sweden and Institute of Medical Biochemistry[2], University of Aarhus, Aarhus, Denmark.

Reprint requests to: S. Ingemansson, M.D., Department of Surgery, University of Lund, S-221 85 Lund, Sweden.

Abstract

Six patients with carcinoid tumors were investigated by simultaneous caval, aortal and portal vein catheterization in conjunction with selective pancreatic and intestinal vein catheterization. Blood samples thereby obtained were assayed for substance-P-like-immunoreactivity by a specific radioimmunoassay. The levels measured were compared with levels in a reference group of four patients without carcinoids. In addition, tumor tissue was analyzed by cytochemistry and radioimmunochemistry. All tumors were found to contain 5-HT and were hence classified as carcinoids. Four tumors in addition displayed strong substance-P-like-immunoreactivity and were by radioimmunoanalysis found to contain high levels of substance-P-like-immunoreactivity. In two patients plasma substance-P levels were found to be elevated during episodes of flushing. Catheterization revealed arterio-venous differences in substance-P levels over the intestines and liver indicating the presence of primary tumors as well as metastases. It appears that quite a few carcinoids produce abnormally high levels of substance-P-like-immunoreactivity. Conceivably radioimmunoanalytical determinations of this peptide will aid the classification, diagnosis and the preoperative localization of carcinoid.

Substance-P-like-immunoreactivity (SPLI) has been localized in a population of gastrointestinal endocrine cells (5,10,13). The morphology and distribution of the substance-P-like-immunoreactive cells indicated that they belonged to the system of enterochromaffin cells (5,13). In a previous preliminary report (6) we found substance-P-like-immunoreactive cells to occur in two out of three carcinoids. Usually carcinoids are diagnosed late and are difficult to localize preoperatively (2,3,15). New diagnostic tools and localization procedures may therefore be of considerable value. Previously, we have reported on the localization of endocrine tumors by means of pancreatic vein catheterization combined with blood sampling for hormone assay (7,8,9). The good results obtained with this localization procedure prompted a study also of carcinoids. This work was done in order to investigate: 1/ how frequently carcinoids contain substance-P-like-immunoreactive material, 2/ if aortal, caval and portal vein catheterization with selective intestinal vein catheterization for blood sampling and substance-P determination was possible to perform in patients with carcinoid tumors, 3/ if pathologically high local (intestinal and/or hepatic) arterio-venous substance-P differences could be found over carcinoid tumors, 4/ if a pathologically high, local arterio-venous substance-P difference could be used for tumor localization.

Methods

In local anaesthesia simultaneous aortal, caval and portal vein catheterization with selective pancreatic and intestinal vein catheterization for blood sampling and substance-P-assay was performed after 8-10 hours of fasting. From different caval branches including the hepatic vein branches samples were taken in order to localize extraportal tumors. The caval catheter was then placed in the right hepatic vein. The aortal catheter was kept in the coeliac artery during the investigation. The portal catheter was moved to different portal branches including pancreatic veins and different intestinal vein branches. Blood samples were withdrawn from a total of 8-14 intestinal veins. These veins drained the gastrointestinal tract from the stomach to the rectal region. Hence, the bloodsamples "sectioned" the gastrointestinal tract in resectable parts. Fluoroscopy and phlebography revealed the exact position of the catheter tip during the sampling maneuvres (Fig. 6 a, b, c). Blood samples were collected in ice-chilled tubes containing Heparin (14,3 USP Na-Heparin/ml blood) and Trasylol^{R} (500 KIU/ml blood), centrifuged at -4°C for 10 minutes and stored at -20°C until radioimmunoassay for substance-P-like-immunoreactivity was performed according to a previously described method (11).

Surgical specimens were immediately frozen to the temperature of liquid nitrogen in melting Freon-22, freeze-dried, treated with formaldehyde or diethylpyrocarbonate (DEPC) and embedded in paraffin in vacuo. 5 μ sections of DEPC-treated material were deparaffinized and subjected to an indirect immunocytochemical method for the demonstration of sub-

stance-P-like-immunoreactivity as described in detail elsewhere (10). The site of antigen-antibody reaction was revealed with the PAP-method of Sternberger (10,14). Controls were those recommended by Sternberger (14) and included the use of antigen-inactivated antiserum. Sections from formaldehyde-treated specimens were mounted in Entellan[R] (Merck) and examined in a Zeiss 18 fluorescence microscope equipped for epi-illumination. An HBO 50 high pressure mercury lamp was combined with selective filters to give peak excitation at 405 nm. Under these conditions 5-HT emits a bright yellow fluorescence (1). Controls included specimens not treated with formaldehyde.

Material

Four patients without carcinoid tumors were catheterized in order to exclude abdominal malignancy. This group was used as a reference group. Six patients, one female and five males (referred to as patients nos. I, II (the female), III, IV, V and VI) were investigated with conventional methods and then catheterized before explorative laparotomy. Patient no. V was operated upon as an emergency case because of severe gastrointestinal bleeding. During operation blood samples were withdrawn from the tumor artery and veins.

Results

A. Preoperative results. Urinary 5-HIAA were much elevated in patients no. I, III and IV. Preoperative angiography revealed tumors localized in accordance with the peroperative findings (see below) in patients no. I, III, IV, V and VI. Angiography was negative in patient no. II.

B. Tissue analysis. In Table I can be found a summery of relevant clinical details as well as cytochemical and radioimmunochemical results for the individual patients. In Table II the tumor content of substance-P-like-immunoreactive material in patients nos.I, III, IV and V is shown. As seen from the tables all tumors displayed strong fluorescence indicative of 5-HT. Tumors from patients nos.II and IV contained only trace amounts of substance-P-like-immunoreactive material.

C. Plasma analysis. a/The reference group.
In the reference group the SPLI-concentrations in the coeliac artery ($n = 13$) ranged from 5 to 98 pg/ml ($\bar{m} = 38$ pg/ml, median = 39). Hepatic vein values ($n = 13$) ranged from 8 to 70 pg/ml ($\bar{m} = 34$ pg/ml, median = 39 pg/ml). Intestinal vein values ($n = 22$) ranged from 10 to 112 pg/ml ($\bar{m} = 60$ pg/ml, median = 54 pg/ml).

b/ Carcinoid tumor patients.
As seen from Figure 1,patient no. I had initially plasma-SPLI concentrations within the range of the reference group. However, blood from

			SPLI (pg/ml)		
1.	v. lienal. 1	= -	a. coel.	=	54
			v. hep. dx.	=	37
2.	v. lienal. 2	= -	a. coel.	=	-
			v. hep. dx.	=	95
3.	v. lienal. 3	= 40	a. coel.	=	68
			v. hep. dx.	=	58
4.	v. mes. sup.	= 44	a. coel.	=	-
			v. hep. dx.	=	175
5.	v. mes. inf.	= 87	a. coel.	=	55
			v. hep. dx.	=	89
6.	v. mes. inf.	= 44			
7.	v. jejunal.	= 178	a. coel.	=	68
8.	v. mes. sup. (outside GCT)	= 188	a. coel.	=	247
9.	v. p. centr.	= 540			
10.	v. p. centr.	= 557	a. coel.	=	447
			v. hep. dx.	=	742
11.	v. p. centr.	= 486	a. coel.	=	265
			v. hep. dx.	=	356
12.	v. hep. sin. (lat. segm.)	= 216			
13.	v. hep. sin. (lat. segm.)	= 208			

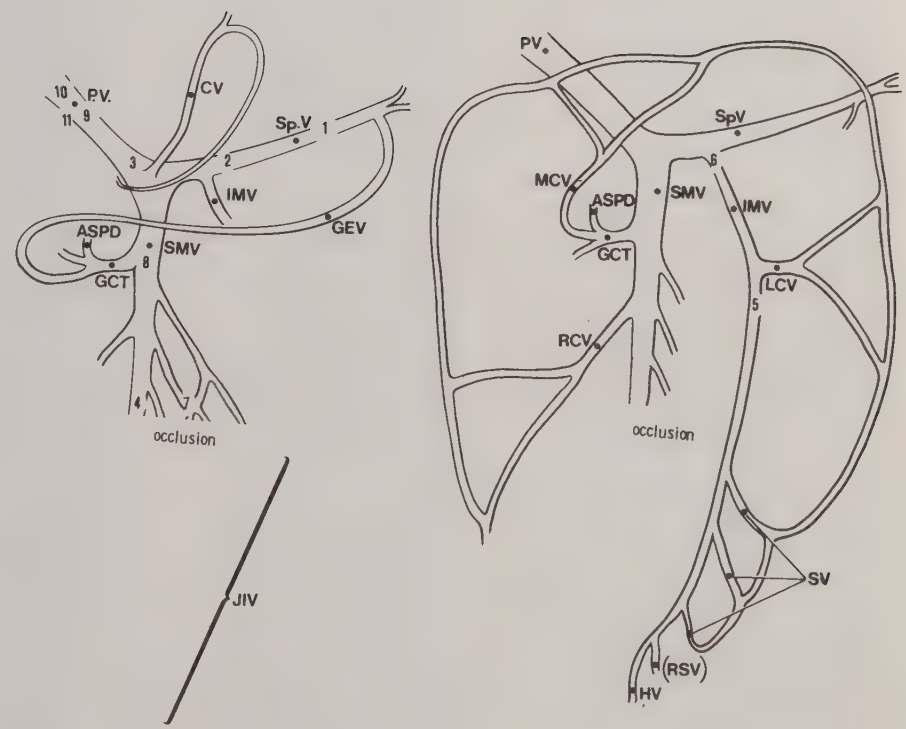

Fig. 1. SPLI-content (pg/ml) in samples withdrawn during catheterization of patient no I.

		Substance-P (pg/ml)
1. v. port. centr.	= missed	a. coel. = missed v. hep. dx = 18
2. v. lienal. dist.	= missed	
3. v. pancreat.	= 37	a. coel. = missed v. hep. dx = 18
4. v. mes. sup.	= 18	
5. v. ileocol.	= 15	a. coel. = 20 v. hep. dx = missed
6. v. ileal.	= 25	
7. v. ileal. prox.	= 27	
8. v. ileal. dist.	= 18	a. coel. = 25 v. hep. dx = missed
9. missed		
10. missed		
11. v. ileal.	= 28	a. coel. = 25 v. hep. dx = 25
12. v. jejunal. dist.	= 27	
13. v. jejunal. mid.	= 25	
14. v. jejunal. prox.	= 27	a. coel. = 25 v. hep. dx = 25
15. v. jejunal. prox.	= 27	a. coel. = 25 v. hep. sin. med. segm. = 25 v. hep. sin. lat. segm. = 20

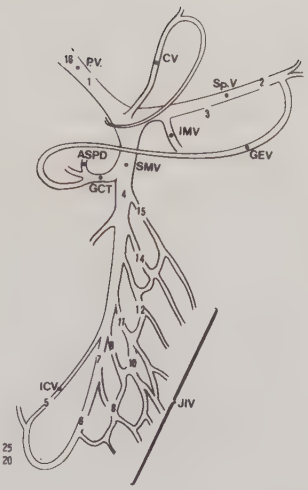

Fig. 2. SPLI-content (pg/ml) in samples withdrawn during catheterization of patient no. II.

		SPLI (pg/ml)
1. v. ileal. prox.	= 30	a. coel. = 70 v. hep. dx. = 50
2. v. port. centr.	= 60	
3. v. port. sin.	= 75	
4. v. port. centr.	= 45	a. coel. = - v. hep. dx. = 20
5. v. lienal. dist.	= 25	
6. v. mes. sup. (below GCT)	= 50	
7. v. ileocol.	= 30	a. coel. = 136 v. hep. dx = 35
8. v. jejunal. dist.	= -	
9. v. port. centr.	= 146	a. coel. = 100 v. hep. dx. = 150
10. v. hep. dx.	= 110	
11. v. hep. sin	= 163	a. coel. = 130 v. hep. = -

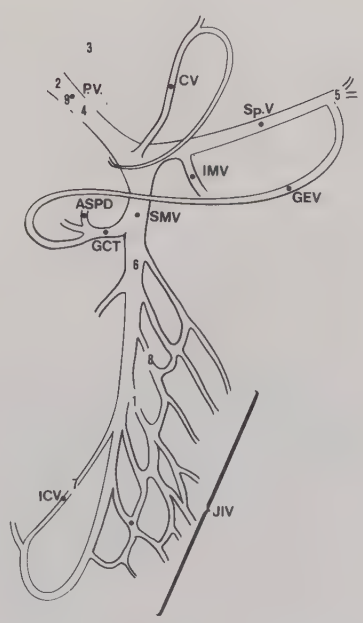

Fig. 3. SPLI-content (pg/ml) in samples withdrawn during catheterization of patient no. III.

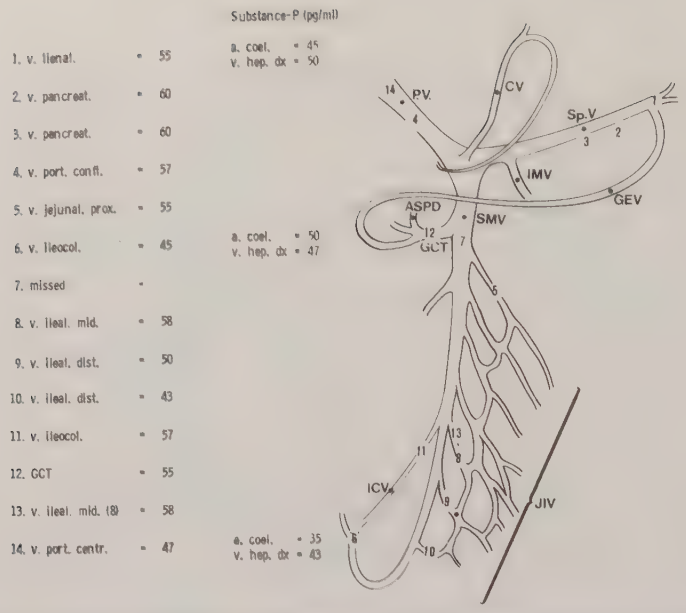

Fig. 4. SPLI-content (pg/ml) in samples withdrawn during catheterization of patient no. IV.

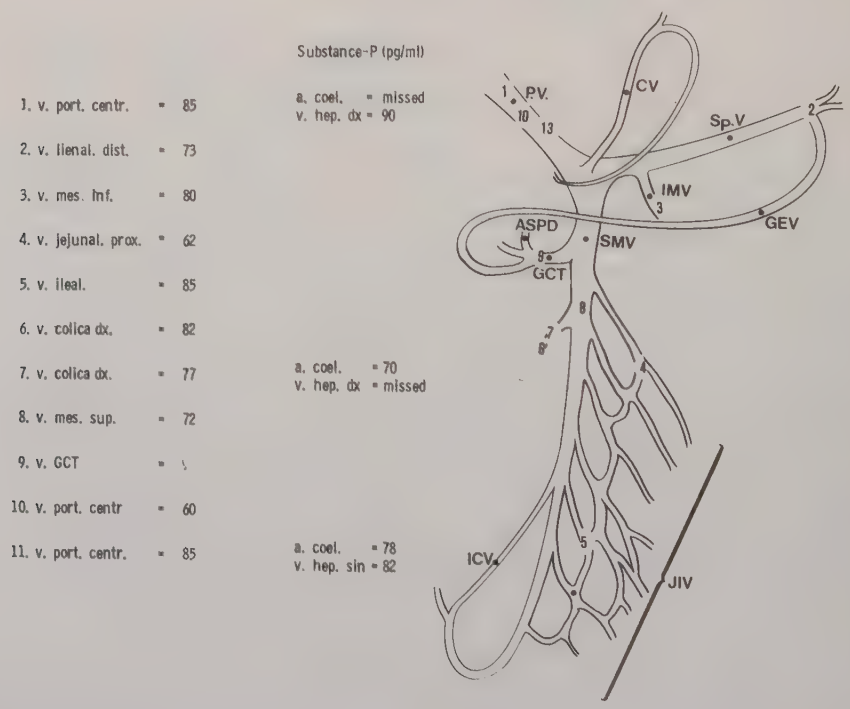

Fig. 5. SPLI-content (pg/ml) in samples withdrawn during catheterization of patient no. VI.

the right hepatic vein in sample no. 4 (Fig. 1) contained greater amounts of substance-P-like immunoreactive material. During this investigation the patient underwent a flushing episode starting when sample no. 7 was withdrawn. It is noteworthy that all subsequent samples contained much elevated substance-P concentration. The highest values were seen in the right hepatic vein and in the main stem of the portal vein indicating intestinal as well as liver tumors releasing substance-P-like immunoreactive material into the blood. Patient no. III (Fig. 3) was troubled with flushing and abdominal discomfort during the end of the investigation. During that time (45-60 minutes) a release of substance-P was noted (sample no. 9,10,11).
In patient no. VI plasma SPLI-concentrations in samples withdrawn from the coeliac artery and the portal vein were within the range of the reference group. In the hepatic vein sample SPLI-concentrations (Fig. 5 sample 1, 11) were raised above the range of the reference group. This finding indicated the presence of liver tumors containing substance-P.

In patients nos. II, IV and V SPLI-concentrations were found to be within the range of the reference group.

D. Operations. Tumors were detected in the distal part of the ileum and in the liver in patient no. I. Patient no. II harboured four tumors (2-6 mm large) in the distal part of the small bowel. No lymphnodes or liver metastases could be detected. The third patient had a large tumor in the ileocaecal region, multiple mesenteric lymphnode-metastases and multiple liver metastases. Patient no. IV had previously been operated upon because of pulmonary carcinoid tumors. Now large metastases were found in the liver but no primary tumor was found in the rest of the abdominal cavity indicating that the liver metastases emanated from the pulmonary carcinoid.

At the emergency operation of patient no. V flushing was noted during surgery when the tumor was palpated. The tumors were localized in the distal part of the small bowel. Resection of the tumor and a lympnode-metastasis was performed.

Patient no. VI had previously had an ileocaecal resection because of carcinoid tumors. A second look was now performed after angiography revealing multiple livermetastases. A careful palpation of the liver revealed three small (4-5 mm) tumors. Enucleation was performed.

All catheterizations were performed without complications.

Discussion

Four out of six patients had carcinoid tumors containing large amounts of SPLI. In one of the patients who had tumors devoid of substance-P (patient no. II) an appendectomy was planned because of low right-sided

Fig. 6 a. Intestinal phlebography during blood sampling in patient no. II (fig. 2, sample no 5-10).

b. Intestinal phlebography during blood sampling in patient no. III (fig. 3, sample no 7).



c. Intestinal phlebography during blood sampling in patient no. VI (fig. 5 sample no 6, 7, 8).

Table I. Carcinoid syndrome, presence of substance-P-like-immuno-reactivity and 5-HT in carcinoid tumors.

		Carcinoid syndrome	5-HT-fluorescence	SPLI*	Tissue content** of SPLI
Pat. no. I	N-B.O.	Yes	Strong	Strong	High
Pat. no. II	B.H.	No	Strong	None	Not performed
Pat. no. III	R.B.	Yes	Strong	Strong	High
Pat. no. IV	E.L.	Yes	Strong	None	None
Pat. no. V	H.E.	No.	Strong	Strong	High
Pat. no. VI	M.G.	No	Strong	Strong	High

* Immuncytochemistry

** Radioimmunoassay

High tissue content of SPLI > 25 ng/g wet tissue weight

Table II. SPLI-content (ng/g wet weight) in tissue from patients no. I, III, IV and V.

	Tissue content of SPLI-material (ng/g wet tissue weight).			
	Pat. no. I	Pat. no. III	Pat. no. IV	Pat. no. V
Primary tumor	220	432		710.7
Non-affected gut mucosa	7.8			21.7
Liver metastases	68	330	0.07-0.57	
Non-affected liver tissue	8.2	7.8		
Lymphoglandular metastases				465.2
Normal liver tissue: (from seven patients)	<0.15 <0.23 <0.23 <0.24 <0.79 <1.30 <0.25			

Table III. SPLI-content (pg/ml) in plasma withdrawn during operation of patient no. V.

	SPLI (pg/ml)
peripheral vein	38 - 35
artery	20 - 32 - 37
tumordraining vein	35 - 30 - 20

abdominal pains. During surgery, however, multiple carcinoid tumors were found en passant. Another patient without SPLI in the tumor was previously operated upon because of pulmonary carcinoid.

The fact that some carcinoid tumors do not produce SPLI is not surprising since the enterochromaffin cell system is now known to be heterogenous with respect to peptide production (5,10,12,13). Thus, while some enterochromaffin cells produce SPLI others seem to produce motilin (12). As yet neither SPLI nor motilin has been localized to bronchial or pulmonary endocrine cells, believed to be the stem cells of pulmonary carcinoids. Immunocytochemical investigations carried out on the present material have shown that all tumors were devoid of motilin. It thus seems probable that carcinoid tumors may be very heterogenous with respect to peptide production as well as cells of origin. It is possible that this heterogenity may reflect differences in the biological behaviour of carcinoid tumors. It should be noted that, as yet, the evidence for SPLI-production by carcinoid tumors has been obtained solely with immunological techniques. Thus it is possible that a substance similar to but not identical with substance-P is produced by the tumors.

Previously substance-P has been suggested as a carcinoid syndrome-causing agent (4). This suggestion was based purely on theoretical considerations of the biological effects of this peptide. The demonstration of substance-P-like material in a substantial proportion of carcinoids as well as the correlation between flushing episodes and increased plasma SPLI-concentrations indicate that this suggestion may well be true although the biological potency of the immunoreactive material is as yet unknown. The increased plasma concentrations of SPLI-material and the arterio-venous differences over the carcinoid tumors indicate that the measurements of this peptide preferably in combination with the triple catheterization technique may be of considerable help in the localization, diagnosis and classification of some carcinoid tumors.

Abbreviations

P V	Portal vein
SpV	Splenic vein
SMV	Superior mesenteric vein
IMV	Inferior mesenteric vein
CV	Coronary vein
GCT	Gastro colic trunk
GEV	Gastroepiploic vein
JIV	Jejunal and ileal veins
ICV	Ileocolic vein
ASPD	Anterior superior pancreatic-duodenal vein
RCV	Right colic vein
MCV	Middle colic vein
LCV	Left colic vein
SV	Sigmoid vein
RCV	Rectosigmoid vein
HV	Hemorrhoidal vein
SPLI	Substance-P-like-immunoreactivity

References

1. Björklund, A., Falck, B. and Owman, C.: In methods of investigative and diagnostic endocrinology, ed. S.A. Berson, Vol. 1. The thyroid and biogenic amines, eds. J.E. Rall and I.J. Kopin. North-Holland Publ. Co., Amsterdam, pp 318, 1972.

2. Boijsen, E., Kaude, J. and Tylén, U.: Radiologic diagnosis of ileal carcinoid tumors. Acta Radiol. (Diagn.) (Stockh.), 15:65, 1975.

3. Costello, C.: Carcinoid tumor metastases. Prospective study of twenty-two patients. Am. J. Surg., 130:756, 1975.

4. Editorial: Lancet, i 539, 1964.

5. Heitz, Ph., Polak, J.M., Timson, C.M. and Pearse, A.G.E.: Enterochromaffin cells as the endocrine source of gastrointestinal substance-P. Histochemistry, 49:343, 1976.

6. Håkansson, R., Bengmark, S., Brodin, E., Ingemansson, S., Larsson, L.-I., Nilsson, G. and Sundler, F.: Substance-P-like immunoreactivity in intestinal carcinoid tumors. Nobel symp. on substance-P. Stockholm 1976. To be published 1977.

7. Ingemansson, S., Lunderquist, A., Lundquist, I., Lövdahl, R. and Tibblin, S.: Portal and pancreatic vein catheterization with radioimmunological determination of insulin. Surg. Gynecol. Obstet. 141:705, 1975.

8. Ingemansson, S., Holst, J., Larsson, L.-I. and Lunderquist, A.: Localization of glucagonomas by pancreatic vein catheterization and glucagon assay. Surg. Gynecol. Obstet., in press 1976.

9. Ingemansson, S., Kühl, K., Larsson, L.-I. and Lunderquist, A.: Islet cell hyperplasia localized by pancreatic vein catheterization and insulin radio immunoassay. Am. J. Surg., in press 1977.

10. Nilsson, G., Larsson, L.-I., Håkansson, R., Brodin, E., Pernow, B. and Sundler, F.: Localization of substance-P-like immunoreactivity in the mouse gut. Histochemistry, 43:97, 1975.

11. Nilsson, G., Pernow, B., Fischer, H.G. and Folkers, K.: Presence of substance-P-like immunoreactivity in plasma from man and dog. Acta Physiol. Scand., 94:542, 1975.

12. Pearse, A.G.E., Polak, J.M., Bloom, S.R., Adams, C., Dryburgh, J. R. and Brown, J.C.: Enterochromaffin cells of the mammalian small intestines as the source of motilin. Virchows. Archiv (Zellpathol.) 16:111, 1974.

13. Pearse, A.G.E. and Polak, J.M.: Immunocytochemical localization of substance-P in mammalian intestine. Histochemistry, 41:373, 1975.

14. Sternberger, L.A.: Immunocytochemistry. Englewood Cliffs, N.J., Prentice Hall, Inc. 1974.

15. Strasberg, Z., Hyland, J., Salem, S., Wilderspin, K. and Tuttle, R.J.: The role of angiography in the management of intestinal carcinoids. Angiology, 26:573, 1975.